OPTOMETRIC Management
FEBRUARY 2011



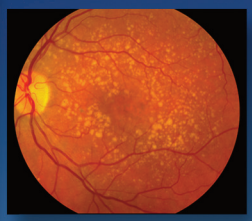
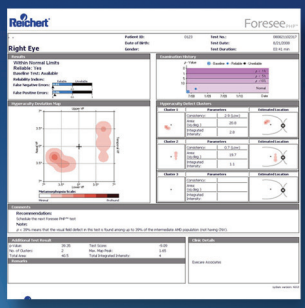

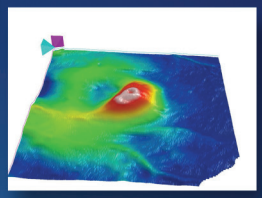

Managing Today's AMD Patient

- Why early diagnosis is so critical
- When to schedule follow-up visits
- How to incorporate new instruments into your practice

Sponsored by

Reichert™
TECHNOLOGIES
Advancing Eye Care. Preserving Sight.™

CONTRIBUTING FACULTY



Kirk Smick, OD, FAAO, moderator

Dr. Smick is Chief of Optometry Services at Clayton Eye Center and an owner of the facility. He graduated from Pacific University College of Optometry and was drafted in the first doctor's draft by the US Army. After serving 5 years of active duty, Dr. Smick began the Clayton Eye Center in Morrow, Ga. in 1974 and continued to serve in the Air National Guard, retiring at the rank of Colonel. He's a highly recognized optometrist in the United States. He has been awarded the "Optometrist of the Year" award for the state of Georgia, where he has served as President of the Georgia Optometric Association, the Georgia State Board of Examiners in Optometry and the Southern Council of Optometrists. He is Chairman of the Continuing Education Committee for the American Optometric Association.



Diana L. Shechtman, OD, FAAO

Dr. Shechtman is an associate professor of optometry at Nova Southeastern University College of Optometry, where she serves as an attending optometric physician at the eye institute and diabetic/macula clinic.
Dr. Shechtman is a member of the American Optometric Association and is a fellow of the American Academy of Optometry, as well as the Optometric Retinal Society. Her area of interest has centered on retinal disease and other ocular pathologies. She has participated in various research projects, and has authored numerous posters and publications.



Jeffry D. Gerson, OD, FAAO

Dr. Gerson graduated from Indiana University School of Optometry in 1997. He went on to complete a residency at the VA medical center in Kansas City, where he concentrated on ocular disease and low vision. Before entering his current practice, he was in several different practices, including 2 ½ years in a retinal referral center, where he had access to numerous diagnostic technologies and participated in multiple clinical trials. His current practice, WestGlen Eyecare in Shawnee, Kan., provides full scope care and retinal consultations for colleagues, and is involved in clinical research.



Steven Ferrucci, OD, FAAO

Dr. Ferrucci, a 1994 graduate of the New England College of Optometry, completed his residency in Primary Care/Hospital Based/Geriatric Optometry at the Sepulveda VA Hospital in Sepulveda, Calif. He is Chief of Optometry at the Sepulveda VA Ambulatory Care Center and Nursing Home. He's also the Residency Director at his site, and an Associate Professor at the Southern California College of Optometry. His emphasis includes therapeutic treatment of glaucoma, cataracts, diabetic retinopathy and age-related macular degeneration. He also performs on-site fluorescein angiography, including injections and digital imaging. Dr. Ferrucci has lectured extensively, with a special interest in diabetes, diabetic eye disease, age-related macular degeneration and fluorescein angiography.

OPTOMETRIC Management

Editorial Staff
CHIEF OPTOMETRIC EDITOR: Walter D. West, OD, FAAO
EDITORIAL MANAGER, SPECIAL PROJECTS: Angela Jackson
EDITOR, SPECIAL PROJECTS: Leslie Goldberg
CONTRIBUTING EDITOR: Sean McKinney

Design and Production
PRODUCTION DIRECTOR: Leslie Caruso
PRODUCTION MANAGER: Bill Hallman
ART DIRECTOR: Michael F. Higgins

Editorial and Production Offices
323 Norristown Road, Suite 200, Ambler, PA 19002
Phone: (215) 646-8700

Business Staff
GROUP PUBLISHER: Roger T. Zimmer
NATIONAL ACCOUNT MANAGER: Jodi L. Smith
EAST COAST REGIONAL SALES MANAGER: Dawn E. Schafer
MARKETING MANAGER: Amy Wauhop
PROMOTIONAL EVENTS MANAGER: Michelle Kieffer
CIRCULATION DIRECTOR: Deb Benward

Copyright 2011. Wolters Kluwer Pharma Solutions, Inc.
All Rights Reserved.

Addressing AMD Early

A more aggressive approach to diagnosing and monitoring AMD can afford better outcomes for patients.

Kirk Smick, OD: Like other primary care optometrists, I've been asked to assume a more active role in the management of age-related macular degeneration (AMD). We need to digest a great deal of new information, including how to incorporate new tests and concepts into private practice. More than ever, we've become partners with specialists in diagnosing, treating and following these patients. Gone are the days when we could detect and refer.

For this roundtable discussion, we've assembled other optometrists with experience in this emerging area of care. They will share their practice-based advice on a variety of issues. Our first topic will be the importance of making an early diagnosis.

Why an early diagnosis?

Dr. Smick: In my one-location practice in Atlanta, 11 eyecare practitioners see about 250 patients each day. A retinal surgeon comes in 2 days a week. Ten years ago, we could refer a patient without consequence long after a choroidal neovascularization (CNV) had formed. Why is it so important to make the diagnosis earlier now?

Jeffrey Gerson, OD: I receive many referrals from colleagues. I find that more patients are at risk for developing AMD and many are experiencing early, intermediate or advanced stages of the disease. It's crucial to identify patients with early AMD so we can try to prevent the formation of choroidal neovascular membranes (CNM). We also need to detect wet macular degeneration as soon as possible.[1] Once a patient develops CNM, we know the outcome will be better if we begin treatment early.[2,3]

Steven Ferrucci, OD: Today our patients can benefit from many treatments, including bevacizumab (Avastin, Genentech), ranibizumab (Lucentis, Genentech), photodynamic therapy (PDT) and combination treatments, such as ranibizumab and PDT or ranibizumab with intravitreal steroids.[4-7]

But we also have new and improved diagnostic technologies, such as optical coherence tomography (OCT), scanning laser polarimetry (GDx, Carl Zeiss Meditec), the Heidelberg III retinal tomograph (HRT) and the Foresee preferential hyperacuity perimeter (PHP) from Reichert, which has been shown to help make an early diagnosis.[8]

When I was a resident, we didn't have treatment options for AMD. An Amsler grid was fine for diagnosis because it didn't matter if the diagnosis was late or early. There was nothing we could do. Now, there is plenty we can do. As the chief of optometry at the Sepulveda VA Medical Center, I serve a geriatric population that benefits significantly from early diagnosis and treatment.

Diana Shechtman, OD: At Nova Southeastern University, where I'm an associate professor, we have access to all of the latest technology. With the advent of anti-VEGF treatment and potential of visual improvement, we've raised the bar, creating an expectation of good outcomes. A CNV of 3000 microns is unquestionably associated with extensive destruction and noticeable vision loss or visual disturbances but at this time, it may not carry a good prognosis following treatment. We need to identify earlier conversion from dry to wet AMD, when the patient still has good visual acuity. Early diagnosis leads to prompt treatment and better visual prognosis.

Dr. Smick: How many patients with dry macular degeneration eventually develop CNV or wet macular degeneration?

Dr. Ferrucci: Studies indicate that 10% to 20% of patients with dry AMD eventually progress to the wet form, which is responsible for most of the estimated 1.75 million cases of advanced AMD in the United States.[9,10]

Dr. Smick: Does everyone on this panel agree that we can't always see when changes have begun simply by looking at the macula clinically when these patients have 20/25 vision?

Dr. Gerson: I agree. The clinical examination is a crucial first step, but advanced technologies are often needed to detect very subtle findings that can aid in diagnosis.

When dry AMD converts to wet

Dr. Smick: When do AMD patients convert from dry to wet AMD? How can we recognize this change in a timely manner?

Dr. Shechtman: If a CNM grows 20 microns a day, that means it increases by 600 microns per month. If you follow up every 3 months, you increase the potential to

identify a conversion much earlier on. Such a patient should be treated with urgency.

Dr. Smick: So 6 months is too long to wait?

Dr. Ferrucci: I believe it is too long. Studies have shown that lesion size is the number one prognostic factor for patients who will respond well to treatment.[11-14] As we've discussed, the sooner we refer these patients for treatment, the better off they'll be. We need to check for changes in both structural and functional vision.

Dr. Gerson: I always try to identify these patients before their vision changes. It is critical.

Dr. Shechtman: We should also be aware of the potential to identify functional vision loss. The Foresee PHP can aid in detecting functional vision loss associated with the conversion of intermediate AMD to wet AMD. It has been clinically validated to be both sensitive and specific.

Dr. Smick: Based on what the panel is saying, early detection means within 3 months of CNV formation, when changes are difficult to see during a clinical exam. The patient may still have excellent vision. What changes in a patient with dry macular degeneration indicate that it's time to increase the frequency of monitoring?

Dr. Shechtman: Once I see structural changes, such as those associated with retinal thinning, pigmentary changes, drusen (in particular soft drusen), which is beginning to coalesce, then I believe the patient needs to be seen more often. Metamorphopsia, visual complaints or any functional change, such as decreased contrast sensitivity, also indicate a need for increased monitoring.

Testing contrast sensitivity

Dr. Smick: Is it realistic for the busy primary care practitioner to do contrast sensitivity testing on these patients?



When I was a resident, we didn't have any treatment options for AMD. An Amsler grid was fine for diagnosis because it didn't matter if the diagnosis was late or early. There was nothing we could do. Now, there is plenty we can do.

— Steven Ferrucci, OD

Dr. Shectman: I think we should consider performing contrast sensitivity testing for patients with AMD. I've seen patients with 20/20 visual acuity and severe retinal thinning, as visualized through an OCT. If you assess contrast sensitivity, you may get a better sense of visual function, which can affect their everyday lives, even if they have no complaints of vision loss.

Dr. Smick: The Amsler grid has long been the gold standard for testing. What role does it play today in this disease process?

Dr. Ferrucci: I frankly don't like using the Amsler grid. Patients don't even use it. Or, if they do, they don't report changes until it's too late, which has been confirmed in studies.[15] The grid is also not sensitive enough to pick up the early retinal changes of AMD or other conditions.

Finally, it's important to note that PHP has already been shown to have greater sensitivity than the Amsler grid in the detection of CNV among patients over 50 years of age.[16] I give patients an Amsler grid but I don't expect much from the test. We are fortunate to have newer technologies to help recognize potential problems.

References

1. Fine AM, Elman MJ, Ebert JE, Prestia PA, Starr JS, Fine SL. Earliest symptoms caused by neovascular membranes in the macula. *Arch Ophthalmol.* 1986;104(4):513-514.
2. Loewenstein A; Richard & Hinda Rosenthal Foundation. The significance of early detection of age-related macular degeneration: Richard & Hinda Rosenthal Foundation lecture, The Macula Society 29th annual meeting. *Retina.* 2007;27(7):873-878.
3. Forte R, Cennamo G, Finelli M, et al. Intravitreal triamcinolone, bevacizumab and pegaptanib for occult choroidal neovascularization. *Acta Ophthalmol.* Oct 14, 2010 [Epub ahead of print]
4. Chan WM, Lai TY, Liu DT, Lam DS. Intravitreal bevacizumab (Avastin) for choroidal neovascularization secondary to central serous chorioretinopathy, secondary to punctate inner choroidopathy, or of idiopathic origin. *Am J Ophthalmol.* 2007;143(6):977-998.
5. Sadda SR, Stoller G, Boyer DS, Blodi BA, Shapiro H, Ianchuelv T. Anatomical benefit from ranibizumab treatment of predominantly classic neovascular age-related macular degeneration in the 2-year anchor study. *Retina.* 2010;30(9):1390-1399.
6. Friberg TR, Tolentino M; for the LEVEL Study Group. Pegaptanib sodium as maintenance therapy in neovascular age-related macular degeneration: the LEVEL study. *Br J Ophthalmol.* May 14, 2010 [Epub ahead of print].
7. Rouvas AA, Papakostas TD, Ntouraki A, Douvali M, Vergados I, Ladas ID. Photodynamic therapy, ranibizumab, and ranibizumab with photodynamic therapy for the treatment of polypoidal choroidal vasculopathy. *Retina.* Oct 13, 2010 [Epub ahead of print].
8. Alster Y, Bressler NM, Bressler SB, et al. Preferential Hyperacuity Perimeter (PreView PHP) for detecting choroidal neovascularization study. *Ophthalmology.* 2005;112(10):1758-1765.
9. Tielsch JM, Javitt JC, Coleman A, Katz J, Sommer A. The prevalence of blindness and visual impairment among nursing home residents in Baltimore. *N Engl J Med.* 1995;332(18):1205-1209.
10. Friedman DS, O'Colmain BJ, Muñoz B, et al. Prevalence of age-related macular degeneration in the United States. *Arch Ophthalmol.* 2004;122(4):564-572.
11. Sivaprasad S, Saleh GM, Jackson H. Does lesion size determine the success rate of photodynamic therapy for age-related macular degeneration? Eye (Lond). 2006;20(1):43-45.
12. Boyer DS, Antoszyk AN, Awh CC, Bhisitkul RB, Shapiro H, Acharya NR; MARINA Study Group. Subgroup analysis of the MARINA study of ranibizumab in neovascular age-related macular degeneration. *Ophthalmology.* 2007;114(2):246-252.
13. Doris N, Hart PM, Chakravarthy U, et al. Relation between macular morphology and visual function in patients with choroidal neovascularisation of age related macular degeneration. *Br J Ophthalmol.* 2001;85(2):184-188.
14. Yamamoto M, Kohno T, Iwami H, et al. Correlation between change in visual acuity and lesion size after photodynamic therapy combined intravitreal pharmacosurgery in age-related macular degeneration with classic choroidal neovascularization. Poster presented during ARVO (Association for Research and Vision in Ophthamology), May 2010.
15. Trevino R, Kynn MG. Macular function surveillance revisited. *Optometry.* 2008;79(7):397-403.
16. Isaac DL, Avila MP, Cialdini AP. Comparison of the original Amsler grid with the preferential hyperacuity perimeter for detecting choroidal neovascularization in age-related macular degeneration. *Arq Bras Oftalmol.* 2007;70(5):771-776.

Better Patient Monitoring

Today's technologies can improve compliance by producing meaningful data for AMD patients and practitioners.

Dr. Smick: Imagine that a primary care optometrist has a patient with dry AMD who has 20/25 visual acuity and the practitioner starts to see changes. How should the patient be educated to ensure effective monitoring?

Dr. Gerson: Getting the patient to buy in to disease management is very important. Someone with 20/25 visual acuity sometimes fails to appreciate the potential dangers of his eye condition. Any test that helps demonstrate the problem and shows that you can monitor for abnormalities will be extremely helpful. When talking to patients, I use the analogy of puzzle pieces, telling them that we need to look at different pieces of the puzzle to figure out what the whole picture looks like. Different tests help educate me so I can educate them on what needs to happen.

Increased monitoring

Dr. Smick: Routine monitoring is critical to detect changes in the earlier stages of AMD, to enable us to refer for earlier treatment, but it can be difficult to get patients to comply with a more frequent follow-up schedule.

Dr. Shechtman: Compliance is always an issue. Consider how difficult it is to get glaucoma patients to use their drops as prescribed, even though they know glaucoma is a blinding disease. Sometimes using the diagnostic tools can help educate the patients and increase awareness. The more proactive we can be, the better off our patients will be. Taking 5 extra minutes to talk to the patient can make a big difference, keeping in mind that our role is both early diagnosis and to decrease the prevalence and progression of the disease.

Dr. Smick: Let's talk about all of the diagnostic tools that are available. Which tools are most valuable for helping us diagnose and manage AMD?

Dr. Ferrucci: In our practice, we have a room designated for macular degeneration testing. It includes a digital camera with fluorescein capabilities, an OCT, the Foresee PHP (Reichert) and the QuantifEye macular pigment optical density instrument (ZeaVision). I believe we need to use multiple tools for AMD, just as we do for glaucoma.[1,2]

Dr. Shechtman: Working at a diabetic and macular clinic/referral center, we have a specialized area for AMD patients. I have access to the QuantifEye, the PHP and a Cirrus HD-OCT (Carl Zeiss Meditec). As much as possible, we should use all of these instruments, which complement each other. Each is unique, measuring a different aspect of the patient's pathology.

When to Use Genetic Testing

Dr. Shechtman: Macula Risk (ArcticDX, Toronto, Ontario) is a simple in-office cheek swab genetic test that can predict genetic predisposition to AMD. In addition, a recent clinical trial showed a 0.831 predictive value risk for progression associated with specific genetic variants (primarily affecting complement factor H "CFH") in conjunction with others factors. That would certainly cause me to follow up at shorter intervals in my AMD patients and use various diagnostic modalities (such as PHP and OCT) to help me detect early progression toward the more advanced stage of the disease.

Dr. Smick: Let me put on my public health hat and ask if we can afford genetic testing if the number of AMD patients increases to nearly 3 million patients by 2020. At a reimbursement rate of $400 per test, won't these costs contribute to bankrupting Medicare?

Dr. Gerson: Genetic testing is preventive medicine, which saves as much or more money than it costs because it separates patients who don't need continuous follow-up from those who are at much higher risk. A $400 test can save $400 in yearly exam fees for lower-risk patients. If testing tells you that a patient is at a much higher risk of converting, the money is well spent on routine monitoring with PHP or OCT because your tests will produce a high yield.

Dr. Smick: You make a convincing argument. I believe genetic testing will increase. More optometrists are using this test, which also reinforces our position as primary care providers.

How is PHP different?

Dr. Smick: How would you say the PHP compares to the traditional visual fields used to monitor glaucoma? What value does this new technology offer in diagnosing and managing AMD patients?

Dr. Gerson: The PHP is comparable to a regular perimeter, but there are some significant differences. During the test, a patient observes a line of dots moving horizontally across a screen. Using a special pen, the patient marks any deviations that he sees on the dotted line. The PHP produces varying magnitudes of artificial distortions of the straight horizontal dotted line. These artificial distortions compete with pathological distortions caused by AMD and by a rise in retinal pigment epitheli-

um (RPE). If a patient has a pathological distortion that is more pronounced than the artificial distortion, the patient will use the pen to mark his pathological distortion. This process is called preferential looking. The RPE abnormalities that cause these changes are often related to choroidal neovascular membranes (CNM) in AMD patients.

Patient response patterns are recorded and analyzed by a customized algorithm, which compares the responses to a normative database. Test results are generated immediately in a detailed report. PHP technology can identify CNV lesions when they are small and when visual symptoms could still go unnoticed.

Dr. Smick: Do you find the PHP to be accurate?

Dr. Gerson: Absolutely — the printout is also very helpful because it provides a plot that's similar to what an Amsler grid provides. The printout identifies trouble spots in a patient's field of vision, showing you where in the macula those trouble spots might be. It provides probability numbers and shows changes over time.

Dr. Smick: I use the PHP as well. I like putting the printouts in the chart. Each time a patient visits, we repeat the test, so he can see how he's doing. It encourages compliance.

Planning for Your AMD Diagnostic Upgrade

Dr. Smick: How many patients do you need to test to make the equipment purchase worthwhile?

Dr. Gerson: First, you need to factor tax deductions into the price. If you're using CPT code 92082, it's generally reimbursing at $50 per test. That means you may need to do 400 exams to break even on a $20,000 piece of equipment. If you're seeing patients 4 times a year, you will break even on 100 patients. Or you may need to wait longer to pay for your investment. The broader question is whether you can grow your practice with this technology. If your patients need the test, the answer is yes.

Dr. Smick: How do you manage your workflow when administering PHP, particularly on a routine basis?

Dr. Ferrucci: A well-trained technician can conduct PHP in 3 to 5 minutes. I like to have patients come back when the technician can do the test and I can review the results at a convenient time. But sometimes we have to do the test on the same day as the exam for patients who travel long distances.

Dr. Gerson: We always ask patients to return, usually when I'm out of the office. You can bill for the PHP test and a level 1 follow-up visit. It's an efficient use of support staff time.

Dr. Smick: Carriers have different rules for when you're out of the office, so you need to check on that. Like Dr. Gerson, we always schedule the patients to come back and usually incorporate this test with an office visit, a CPT code 99212. The Medicare CPT code guide specifies that this type of testing has to be ordered. Make sure your chart reflects this.

Dr. Gerson: Often, if I'm seeing a patient back for a PHP, I'll have the patient back the week before the exam to do the PHP. Then, when he returns for the exam, I review the results with him.

Dr. Shechtman: We don't do a PHP when the patient is dilated, so that is another reason for us to schedule the test separately. I also don't want the exam to last too long.

Key PHP functions

Dr. Shechtman: The PHP is reliable, reproducible and sensitive. It certainly can help evaluate an early functional change, which may or may not occur with associated structural change. Just as we find in glaucoma, both functional and structural changes need to be assessed and monitored in patients with AMD.

Dr. Smick: How does the nomenclature of visual fields — such as 10-2 visual fields or microperimetry — relate to PHP?

Dr. Shechtman: PHP principles rely on vernier acuity. If a patient has a growth under the RPE, a displacement of RPE cells can occur with overlying photoreceptors displacement. The PHP is quite sensitive in detecting this. Visual field defects don't rely on the same principle. PHP and microperimetry are not exactly synonymous.

Dr. Ferrucci: The Humphrey visual field test was designed to check for glaucomatous changes, based on a glaucoma patient database. The Foresee PHP has been designed to evaluate AMD and CNM, based on an AMD patient database.

Reducing referrals

Dr. Smick: I want to talk about another area of AMD care where better information is making a difference. Primary care optometrists have been accused of referring too much. In the past, many of us would refer AMD patients to retinal specialists at the first sign of trouble, as if we were afraid of patients going blind on our watch.

But a new approach is emerging. We're much more informed about the significance of retinal changes. Part of this progress is linked to the diagnostic technology we're discussing.

Dr. Gerson: In the past, if someone demonstrated a change in vision and we saw some drusen, we assumed a CNM was involved, even though drusen could have been causing the change. Now, if I look clinically and don't see a CNM developing, I can use PHP to confirm this finding and confidently hold off on referring. We should refer patients only when they need treatment. This approach will reinforce our position as the doctors our patients should see for follow-up care.

Dr. Shechtman: Neovascular AMD affects more than 1.75 million Americans aged 40 and older, and that num-



In the past, if someone demonstrated a change in vision and we saw some drusen, we assumed a CNM was involved, even though drusen could have been causing the change.

Jeffry D. Gerson, OD, FAAO

ber is expected to grow to nearly 3 million by 2020.[3] Another 7 million already have large drusen (≥125 microns) in one or both eyes.[3] There aren't enough retina specialists to see all of these patients. In essence, they will become our patients, thus we need to take a proactive role in the evaluation and management of them.

Follow-up frequency

Dr. Smick: In our increased primary care role, how often should AMD patients return for monitoring with PHP and other tests? Is every 3 months standard?

Dr. Gerson: No single technology should dictate how often we see a patient. I talk to my patients about family history and lifestyle, including nutrition and smoking. I also order genetic testing to assess risk levels. This information helps me determine when to bring patients back for OCT or PHP. These interventions also show patients why I'm asking them to return, whether it's every 3 months, 4 months or 6 months. They understand that I've asked questions, that I've done tests and they know there's a reason I'm asking them to return.

Evaluating risk factors

Dr. Ferrucci: Smoking has been found in multiple studies to be the number one modifiable risk factor for AMD, followed by poor nutrition and increased body mass index.[4-6] Patients can reduce the risk of developing AMD by making lifestyle changes — quitting smoking, reducing high blood pressure, decreasing body mass index, increasing consumption of dark green leafy vegetables, taking vitamin supplements and wearing sunglasses that block ultraviolet and high-energy radiation.[7,8]

All of these factors should be considered when counseling patients. I also like to get a baseline PHP, much as you would to establish a baseline visual field for a glaucoma patient. I think patients with intermediate AMD or worse require quarterly PHP evaluations. The growth of choroidal vascular membranes warrants this degree of follow-up.

Future trends

Dr. Smick: I want to conclude our discussion by looking into our diagnostic crystal ball. Do you envision additional uses for PHP in the future?

Dr. Gerson: In Kansas City, we see many patients with histoplasmosis and PHP could help. The test demonstrates good sensitivity and specificity for related choroidal neovascular membranes. It's also useful in conditions that don't involve choroidal neovascular membranes, such as hydroxychloroquine (Plaquenil) toxicity.[9,10]

Dr. Shechtman: Other potential uses of PHP in the future could include other causes for CNV such as myopic degeneration, histoplamosis and angioid streaks. The test is approved for patients with macular degeneration, but I believe it could play a role in other diseases.

Dr. Gerson: Another issue that will become more important going forward is the use of a home version of PHP. This device will complement the office-based version. Neither will replace the other. The effect of supplementary, home use of PHP will be increased test frequency, adding to the benefit of this technology as a monitoring device.[11]

Increasing Optometry's Role

Dr. Smick: We're excited about the future of optometry and our growing role as primary care providers. We applaud our colleagues for the progress they've made in the area of diagnosis, tracking and treatment of AMD. As we acquire more information and better technology, we'll become even better equipped to provide top-notch care. For the present time, we have to emphasize the need for speedy referrals to those specialists who utilize the modern injections for this terrible disease. We need to spread the word that there is technology available to greatly assist in diagnosing dry-to-wet conversions.

References

1. Congdon N, O'Colmain B, Klaver CC, et al. Causes and prevalence of visual impairment among adults in the United States. *Arch Ophthalmol.* 2004;122(4):477-485.
2. Lee PP, Feldman ZW, Ostermann J, Brown DS, Sloan FA. Longitudinal prevalence of major eye diseases. *Arch Ophthalmol.* 2003;121(9):1303-1310.
3. Friedman DS, O'Colmain BJ, Muñoz B, et al. Prevalence of age-related macular degeneration in the United States. *Arch Ophthalmol.* 2004;122(4):564-572.
4. Wong IY, Koo SC, Chan CW. Prevention of age-related macular degeneration. *Int Ophthalmol.* Sept. 23, 2010 [Epub ahead of print].
5. Klein R, Cruickshanks KJ, Nash SD, et al. The prevalence of age-related macular degeneration and associated risk factors. *Arch Ophthalmol.* 2010;128(6):750-758.
6. Raniga A, Elder MJ. Dietary supplement use in the prevention of age-related macular degeneration progression. *N Z Med J.* 2009;122(1299):32-38.
7. Age-Related Eye Disease Study Research Group. Risk factors associated with age-related macular degeneration. A case-control study in the age-related eye disease study: Age-Related Eye Disease Study Report Number 3. *Ophthalmology.* 2000 Dec;107(12):2224-2232.
8. Chaine G, Hullo A, Sahel J, et al. Case-control study of the risk factors for age related macular degeneration. France-DMLA Study Group. *Br J Ophthalmol.* 1998;82(9):996-1002.
9. Anderson C, Pahk P, Blaha GR, et al. Preferential Hyperacuity Perimetry to detect hydroxychloroquine retinal toxicity. *Retina.* 2009;29(8):1188-1192.
10. Kwiecie S, Szaflik JP, Szaflik J. Diagnostic difficulties in patients with macular lesions. *Klin Oczna.* 2007;109(4-6):205-208.
11. Loewenstein A, Ferencz JR, Lang Y, et al. Toward earlier detection of choroidal neovascularization secondary to age-related macular degeneration: multicenter evaluation of a preferential hyperacuity perimeter designed as a home device. *Retina.* 2010;30(7):1058-1064.



Rethink Amsler.

Since the introduction of the Amsler Grid in 1947, the management of AMD has evolved substantially… New treatments for Wet AMD are now available that can preserve, and in some cases, return lost vision to patients. However, early detection remains the vital precursor to saving vision and maximizing treatment outcomes.

New treatments deserve new effective methods of detection. The Reichert **Foresee PHP®** **Preferential Hyperacuity Perimeter** provides an unsurpassed level of sensitivity and specificity in detecting recent onset Choroidal Neovascularization. Manage your AMD patients with the latest technology available, ensuring treatment begins as early as possible.

See Wet AMD before your patients do, with Foresee PHP.

Learn more at **www.reichert.com**



SECO
Booth 1423
Int. Vision Expo East
Booth MS1113

Reichert™
TECHNOLOGIES
Advancing Eye Care. Preserving Sight.™

© 2011 Reichert, Inc. All rights reserved. 01/11. Reichert and Foresee PHP are registered trademarks of Reichert, Inc. Reichert Technologies and "Advancing Eye Care. Preserving Sight." are trademarks of Reichert, Inc. All other trademarks are properties of their respective owners.